

# MANAGING SJÖGREN SYNDROME

The systemic autoimmune condition can have serious ocular consequences.

BY MELISSA BARNETT, OD, FAAO, FSLs



Sjögren syndrome is an autoimmune condition that can lead to ocular surface disease as a result of dysfunction of the lacrimal functional unit (LFU).<sup>1</sup> Antibodies directed against muscarinic receptors within the lacrimal and salivary glands cause aqueous deficient dry eye and dry mouth, the hallmark symptoms of Sjögren syndrome. Advances in

our knowledge of the syndrome and identification of genetic and environmental risk factors have allowed researchers to pursue therapeutic interventions directed at multiple targets with novel therapies.

The LFU is a network composed of ocular surface tissues, the main and accessory lacrimal glands, meibomian glands, conjunctival goblet cells, epithelial cells, and the neural connections of all of these elements. The LFU receives input from sensory tissues and connects to the secretory glands that maintain homeostasis of the ocular surface.<sup>2,3</sup> The presence of inflammation in the lacrimal glands disrupts this process and can lead to foreign body sensation, keratoconjunctivitis sicca, altered tear composition, and tear film instability. Chronic inflammation and disrupted feedback among these components may cause dysfunction or the death of tear-secreting epithelial cells in the lacrimal glands and conjunctiva.

## CHARACTERISTICS

In addition to dry eye and dry mouth, characteristics of primary Sjögren syndrome include a combination of positive serum autoantibodies, reduced salivary secretion, and a positive focus score on minor salivary gland biopsy. Secondary Sjögren syndrome includes all of the classifications of the primary syndrome with the addition of autoimmune connective tissues disease, most commonly rheumatoid arthritis. Women comprise 90% of patients with Sjögren syndrome. Sjögren's syndrome is highly diagnosed in both men and women.

Patients often have reduced concentrations of substances produced by the lacrimal gland to support and protect the ocular surface including mucins, growth factors, and antimicrobial and antiinflammatory factors.<sup>4</sup> Numerous mechanisms may contribute to lacrimal gland dysfunction,

including the cholinergic blockade from autoantibodies to muscarinic acetylcholine receptors, inhibition of acinar secretion by inflammatory cytokines, cytokine-mediated epithelial cell death, and replacement of acini by lymphocytes.<sup>5-9</sup> Inflammatory mediators may also contribute to ocular surface epithelial disease.

## SYMPTOMS

Ocular symptoms include irritation, dryness, pain, stinging, burning, itching, epiphora, and blurring or interrupted vision. These symptoms can negatively affect quality of life and can cause photophobia due to tear dysfunction and ocular surface disease.<sup>10</sup> Clinically significant ocular surface disease in Sjögren syndrome patients may be present even with normal tear production and tear volume.

## DIAGNOSIS

An antibody test often performed for the diagnosis of rheumatoid arthritis can detect elevated levels of the key diagnostic markers for Sjögren syndrome: anti-Ro/SSA, anti-La/SSB, and antinuclear antibodies, or ANA.<sup>11</sup> Patients will typically have elevated levels of immunoglobulins and possibly an elevated erythrocyte sedimentation rate, which is also an indicator of inflammatory disease.

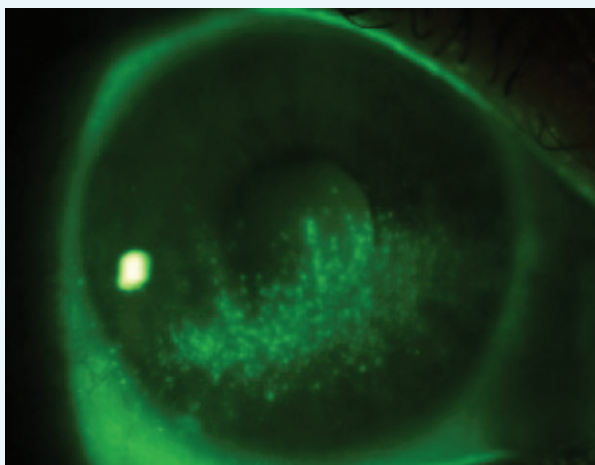


Figure 1. Sodium fluorescein corneal staining.

In addition to the traditional biomarkers, ANA, SSA, SSB, and rheumatoid factor (RF), other antibodies in salivary gland protein-1, carbonic anhydrase, and parotid secretory protein provide high specificity and sensitivity and may be useful markers for early identification of Sjögren syndrome.<sup>12</sup> Sjö (Bausch + Lomb) is a relatively new testing option for diagnosis of Sjögren syndrome, easily performed with a finger prick.

### MANAGEMENT

Management of Sjögren syndrome involves eyelid hygiene treatments and topical therapies such as artificial tears, lubricant ointment, autologous serum, topical cyclosporine (Restasis; Allergan), and topical lifitegrast (Xiidra; Shire). Adjunctive therapies might include moisture-preserving eye-wear, daytime dry eye relief (glasses with moisture reservoirs used to increase humidity), humidifiers, and oral nutritional supplementation.

Research suggests that nutritional supplements containing omega fatty acids can be helpful in reducing inflammation in dry eye disease and meibonian gland dysfunction. A randomized, double-masked clinical trial of HydroEye (ScienceBased Health) examined the effects of long-term nutritional supplementation for moderate to severe keratoconjunctivitis sicca. Patients using HydroEye demonstrated a significant improvement in symptom scores and fewer irritation symptoms compared with those in the placebo group.<sup>13</sup> The HydroEye group had significantly lower levels of inflammatory markers and significantly enhanced corneal smoothness compared with the placebo group.

In addition to omega-3 fatty acids and nutrient cofactors, HydroEye contains 235 mg of gamma linolenic acid (GLA), an omega-6 fatty acid that efficiently reduces inflammation and has demonstrated efficacy in treating Sjögren syndrome.<sup>14</sup> GLA is the precursor of the anti-inflammatory prostaglandin E1, found in the tears, lacrimal gland, and conjunctiva, which supports the production of aqueous. Sourced from black currant seed oil, GLA is not easily obtainable through dietary means and must be obtained through supplementation. Supplemental GLA has been shown to increase prostaglandin E1—an indicator of anti-inflammatory activity—to improve ocular surface status, and to reduce dry eye symptoms.<sup>15</sup>

### CASE STUDY

A 58-year-old white woman presented for an eye examination, referred by her rheumatologist. Her complaints included eye pain, aching of the eyes, swelling, a sandy sensation, and difficulty reading small print, especially when using a computer. She used artificial tears as needed. Her medical history was significant for systemic Sjögren syndrome.

Her BCVA was 20/20 in each eye. Slit-lamp examination showed upper eyelid ptosis in both eyes. Moderate nasal and

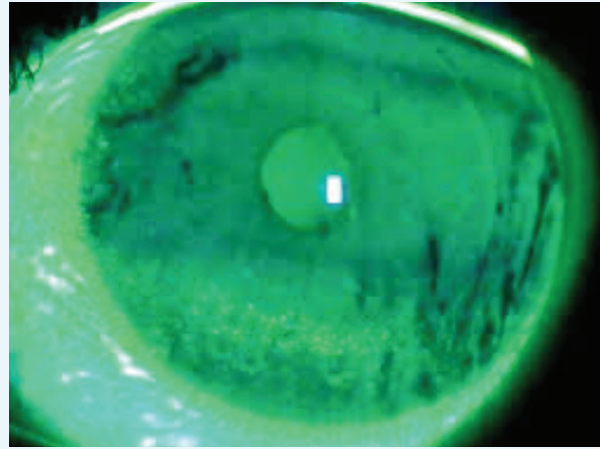


Figure 2. Irregular tear film with inferior sodium fluorescein corneal staining.

temporal sodium fluorescein staining was present in both eyes (Figures 1 and 2). Mild temporal lissamine green staining was present in both eyes and nasal in the left eye (Figure 3). Reduced tear meniscus and map dot fingerprint dystrophy was present in both eyes. Corneal evaluation indicated grade 1+ inferior corneal staining in both eyes (left eye > right eye). Tear breakup time was 3 seconds in the right eye and 4 seconds in the left eye. Both eyes demonstrated normal results for intraocular pressure, dilated retinal examination, color vision, Amsler grid testing, optical coherence tomography of the macula, and 10-2 visual field testing.

Management options were discussed with the patient. She declined surgical correction for ptosis and began a treatment regimen including eyelid hygiene (warm compresses for 5 to 10 minutes daily), topical cyclosporine ophthalmic emulsion 0.05% (Restasis; Allergan) twice daily, nonpreserved artificial tears four times daily or as needed, lubricant ointment at bedtime, and frequent breaks from the computer. Additionally, the patient started taking HydroEye nutritional supplements.

The patient was compliant with the prescribed regimen, and at the 1-month visit she reported significant improvement with no dryness, pain, or ache in either eye and a lessening of the sandy sensation. She noticed improved vision and no longer woke up during the night due to eye pain. There was some improvement of corneal and conjunctival staining, and tear breakup time was 4 seconds in each eye.

Punctal plugs, nighttime moisture goggles, and a humidifier were later added for additional relief. The patient continues to use cyclosporine and take HydroEye supplements but has decreased use of lubricants. The patient has managed her symptoms well, with only slight fluctuations in dry eye symptoms in the past 4 years.

*(Continued on page 44)*

(Continued from page 40)

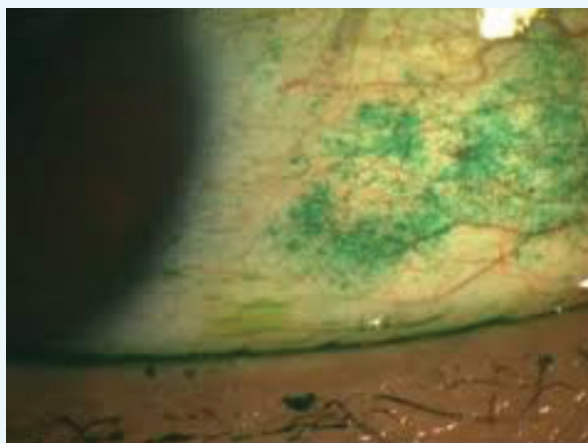


Figure 3. Lissamine green conjunctival staining.

## CONCLUSION

We now have the ability to provide ocular relief for patients with Sjögren syndrome. Early detection is imperative to prevent lymphoma and other systemic complications. By combining patient history, laboratory and ocular testing, and coordination of care with rheumatology and dentistry for salivary testing, we can increase the possibility of early detection and treatment. ■

1. Pflugfelder SC. What causes dryness in Sjögren's syndrome patients and how can it be targeted? *Expert Rev Clin Immunol*. 2014;10(4):425-427.
2. Stern ME, Beuerman RW, Fox RI, et al. The pathology of dry eye: the interaction between the ocular surface and lacrimal glands. *Cornea*. 1998;17(6):584-589.
3. Stern ME, Schaumburg CS, Pflugfelder SC. Dry eye as a mucosal autoimmune disease. *Int Rev Immunol*. 2013;32(1):19-41.
4. Alex A, Edwards A, Hays JD, et al. Factors predicting the ocular surface response to desiccating environmental stress. *Invest Ophthalmol Vis Sci*. 2013;54(5):3325-3332.
5. Humphreys-Beher MG, Brinkley L, Purushotham KR, et al. Characterization of antinuclear autoantibodies present in the serum from nonobese diabetic (NOD) mice. *Clin Immunol Immunopathol*. 1993;68(3):350-356.
6. Kovacs L, Marcinovits I, Gyorgy A, et al. Clinical associations of autoantibodies to human muscarinic acetylcholine receptor 3 in primary Sjögren's syndrome. *Rheumatology*. 2005;44(8):1021-1025.
7. Zoukhri D, Macari E, Kublin CL. A single injection of interleukin-1 induces reversible aqueous-tear deficiency, lacrimal gland inflammation, and acinar and ductal cell proliferation. *Exp Eye Res*. 2007;84(5): 894-904.
8. Rahimy E, Pitcher JD III, Pangelinan SB, et al. Spontaneous autoimmune dacryoadenitis in aged CD25KO mice. *Am J Pathol*. 2010;177(2):744-753.
9. Nguyen CQ, Peck AB. Unraveling the pathophysiology of Sjögren syndrome-associated dry eye disease. *Ocul Surf*. 2009;7(1):11-27.
10. Uchino, M, Schaumberg, DA. Dry eye disease: impact on quality of life and vision. *Curr Ophthalmol Rep*. 2013;1(2):51-57.
11. Chen KS, Jiang MC, Li CJ, et al. Discrimination between Sjögren's and non-Sjögren's sicca syndrome by sialoscintigraphy and antibodies against alpha-fodrin and Ro/La autoantigens. *J Intern Med Res*. 2009;37(4):1008-1096.
12. Shen L, Suresh L, Lindemann M, et al. Novel autoantibodies in Sjögren's syndrome. *Clin Immunol*. 2012;145(3):251-255.
13. Sheppard JD Jr, Singh R, McClellan AJ, et al. Long-term supplementation with n-6 and n-3 PUFAs improves moderate-to-severe keratoconjunctivitis sicca: a randomized double-blind clinical trial. *Cornea*. 2013;32(10):1297-1304.
14. Aragona P, Bucolo C, Spinella R, et al. Systemic omega-6 essential fatty acid treatment and PGE1 tear content in Sjögren's syndrome patients. *Invest Ophthalmol Vis Sci*. 2005;46:4474-4479.
15. GLA & EPA / DHA Blend Reduces Inflammatory Marker in Dry Eye. ScienceBased Health Edufacts Scientific Write-ups. <http://www.sciencebasedhealth.com/ContentPage.aspx?WebpageId=497>. Accessed October 5, 2016.

### Melissa Barnett, OD, FAAO, FSLs

- Principal Optometrist, UC Davis Eye Center, Sacramento, California
- (916) 734-7851; drbarnett@ucdavis.edu
- Financial disclosure: consultant to Acculens, Alcon, Alden Optical, Allergan, Bausch + Lomb, Coopervision, JJVC Vistakon, Novabay, Paragon Biotech, Shire, STAPLE Program, and Visionary Optics